

Accessory muscle in the hypothenar region: A functional approach

N. Bakinde*, P. Yotovski, T. Voigt, G. Rager

Department of Medicine, Anatomy Unit, University of Fribourg, Route Albert Gockel 1, Fribourg CH-1700, Switzerland

KEYWORDS

Hypothenar;
Muscle;
Morphology;
Function;
Man

Summary

An accessory muscle was found in the hypothenar region on both hands during routine cadaver dissection. This muscle originated from the tendon of the flexor carpi radialis, crossed the palma manus region superficially and inserted together with the abductor digiti minimi muscle into the ulnar aspect of the basis of the fifth proximal phalanx. The muscle was supplied by one branch arising from the main trunk of the ulnar nerve.

Abnormalities of the hypothenar muscles have been described by many authors with a focus on their structural aspects, but there is not enough data about the possible functions they could induce. In our study, we try to elucidate the functions of this accessory muscle. We did not name the variant muscle as it has various functions, each similar to that of individual hypothenar muscles.

Introduction

Hypothenar muscle variations have been reported earlier in much detail in regards to their morphology and variable innervation pattern (Bucher, 1943; King and O'Rahilly, 1950; Wahba et al., 1998; Bozkurt et al., 2004). These reports have focused on the structural aspects of the variants. To our knowledge, the variant muscle described here differed markedly in its origin, insertion, innervation pattern and location (bilateral) from those reported previously. Owing to the various possible

movements, which could be executed by this variant, we have not proposed a name for this muscle. The aim of our study was to combine the functional and the structural changes associated with these anatomical presentations.

Case report

During a routine dissection course at the Anatomy Unit of the University of Fribourg, Switzerland, an accessory muscle was discovered in a 77-year old

*Corresponding author. Tel.: +41 26 300 8563; fax: +41 26 300 9733.
E-mail address: nicolas.bakinde@unifr.ch (N. Bakinde).

male on the palmar side of both hands (Figs. 1–5). This muscle originated from the tendon of the flexor carpi radialis (Figs. 1 and 2), passing obliquely palmar to the retinaculum flexorum and the ulnar nerve through Guyon's canal. It crossed the palma manus region superficially and lay on the radial side of the abductor digiti minimi (Fig. 3). About 1 cm proximal to its insertion, the variant muscle received fibers from the abductor digiti minimi (Fig. 3 inset). Both muscles inserted together into the ulnar aspect of the base of the fifth proximal phalanx (Fig. 5).

The muscle was approximately 10.5 cm in length, including the 2 cm portion proximal to a virtual line connecting the os pisiforme and the os scaphoideum. It had the same spindle-shaped aspect and about the same diameter as the flexor digiti minimi, that is approximately 0.5 cm. The measurements were made at the thickest point. All other muscles classically observed in the palma

manus were present and did not show any abnormality. Further, no deviation of either the palmaris longus muscle or the palmar aponeurosis from the common status could be noted. The innervation came directly from the main trunk of the ulnar nerve (Fig. 4), just before its division into the superficial and the deep branch at the level of the pisiform bone. The superficial branches of the ulnar nerve lay under the variant muscle.

Discussion

For some years, case reports on anomalies of the intrinsic structures of the hypothenar region have been increasing, be it from dissecting rooms or from clinics. Hypothenar muscle variations, including abnormality, absence or multiplication, have been reported (Bucher, 1943; King and O'Rahilly, 1950; Wahba et al., 1998; Wingerter et al., 2003).

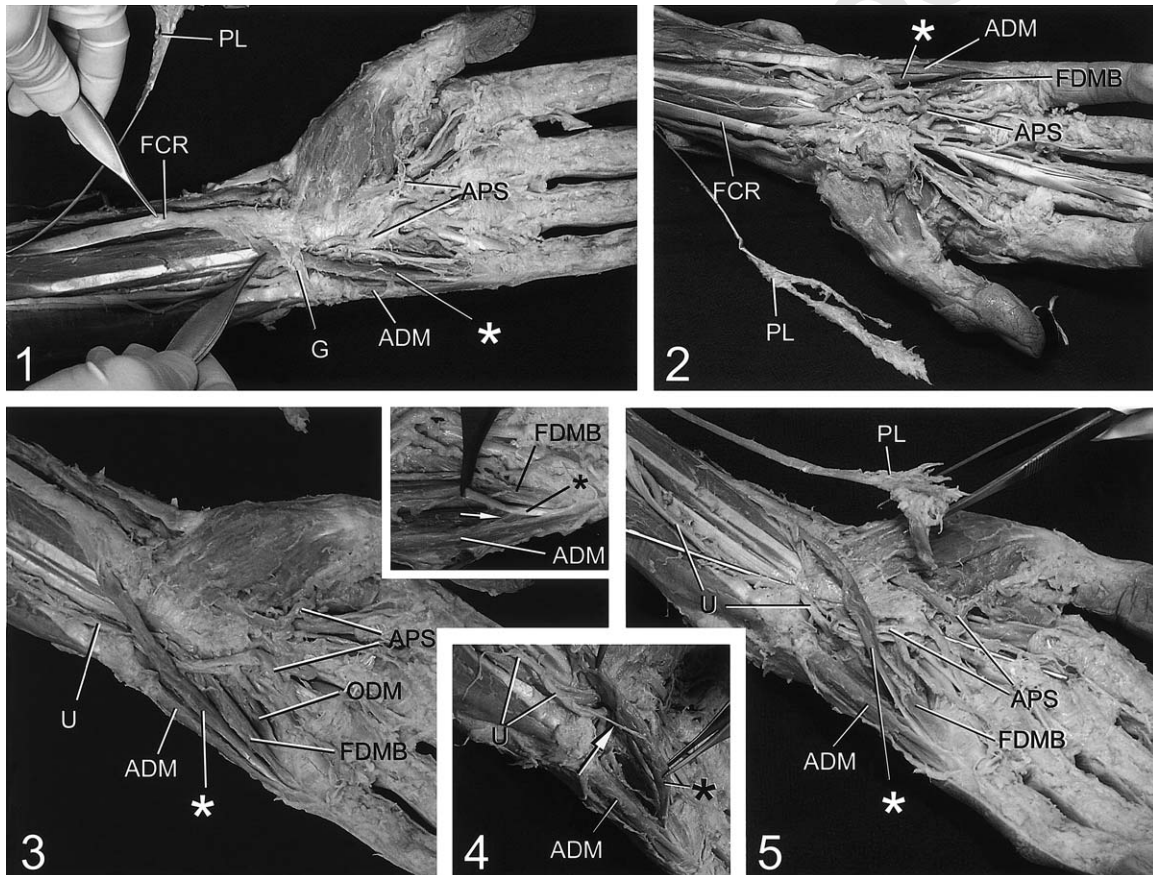


Figure 1–5. Different dissection levels of the palmar side of the hand. (1) The accessory muscle in the Guyon's canal. (2) The variant muscle on the right hand (accidentally sectioned). (3) Oblique course of the muscle palmar to the retinaculum flexorum (the Guyon's canal is open). 3 inset: Fibers of the abductor digiti minimi (→) attached to the tendon of the accessory muscle. (4) Innervation of the variant muscle: motor branch (→) arising from the main ulnar trunk. (5) Common insertion of the variant with the abductor digiti minimi. *, Accessory muscle; ADM, abductor digiti minimi; PL, palmaris longus; FCR, flexor carpi radialis; U, ulnar nerve; FDMB, flexor digiti minimi brevis; ODM, opponens digiti minimi; APS, arcus palmaris superficialis; G, Guyon's canal.

There is much data about the anatomic description of these variants and their respective variable and abnormal motor innervation (Wahba et al., 1998; Gudemez et al., 2002; Bozkurt et al., 2004).

The most frequent muscle variants documented in the literature on the hypothenar region relate to the abductor digiti minimi (Harvie et al., 2004), which has been reported to have a very variable origin and to insert into the proximal phalanx or into the extensor aponeurosis (Putz and Pabst, 1999; Tillman and Töndury, 1987; Kanaya et al., 2002; Murata et al., 2004). None of the many and varied case reports, however, matches the single constellation we saw in this study; the variant was found in both hands, was approximately as thick as the flexor digiti minimi and was innervated from a branch of the main trunk of the ulnar nerve. An anomalous muscle with similar origin has been described earlier by Netscher and Cohen (1998) with no indication of the insertion pattern. Wingerter et al. (2003) identified a variant, which inserted similarly to the muscle found here, but originated from the anterior surface of the distal antebrachial fascia. This muscle, described as the flexor digiti minimi brevis, resembles the variant we are facing here as far as the point of insertion is concerned, but has no attachment to the fibers of the abductor digiti minimi.

Many authors have described abnormalities of the hypothenar muscles (Bucher, 1943; Kanaya et al., 2002; Wingerter et al., 2003) with a focus on their morphology and topography. But there is not enough data analyzing the extent of the possible functions most probably executed by these anomalous variants. The aim of our study was, therefore, to combine the functional and the structural peculiarities associated with these anatomical presentations. We resisted the temptation to go into phylogenetical and ontogenetical explanations for the same reasons as given by King and O'Rahilly (1950).

Owing to its origin from the flexor carpi radialis muscle, the most prominent movement to be executed by this variant would be observed when the hand is in a dorsal extension position. The variant described in this study would induce the following movements:

1. In the radio-carpal joint: palmar flexion.
2. In the fifth metacarpo-phalangeal joint:
 - (a) rotation of the fifth finger towards the radial site,
 - (b) flexion of the fifth proximal phalanx,
 - (c) weak abduction of the fifth finger.

Because of its common insertion with the M. abductor digiti minimi, our variant could be considered as its accessory even though abduction is only marginal. Given that pulling on the variant results in a flexion of the small finger, it is well possible to consider it as a flexor digiti minimi variant as did Wingerter et al. (2003), or as a rotator due to the position relative to the fifth metacarpo-phalangeal joint. Even though this variant muscle inserted into the phalanx and not into the metacarpal bone and hence, did not fulfill the principle condition of opponens as stated by Braus and Elze (1929); it is to assume that it does act as an opponens of the fifth finger due to its oblique course from proximal-radial to distal-ulnar.

The ulnar nerve divides into superficial and deep terminal branches. The superficial branch courses at the ulnar side of the superficial arterial arc and lies on the hypothenar muscles most of which are supplied by the deep branches (Leonhardt and Tillman, 1988; Williams et al., 1989; Putz and Pabst, 1999). The muscle variant documented by Wingerter et al. (2003) received fibers from the deep branch of the ulnar nerve. The accessory muscle we are reporting on was supplied by one ulnar motor branch arising from the main trunk, which then bifurcated as mentioned in many reports (Gudemez et al., 2002) to its sensory and deep motor branches distally from the pisiform bone.

Because certain muscle variations can cause various clinical symptoms, it is therefore important to have detailed anatomic knowledge of the corresponding region. The case we described here can assist in the diagnosis and treatment of different pathologies affecting the hand such as compression of the ulnar nerve in the Guyon's canal, Dupuytren contracture and trauma. These details are particularly useful in surgery and orthopedic practice.

References

- Bozkurt, M.C., Tagil, S.M., Ersoy, M., Tekdemir, I., 2004. Muscle variations and abnormal branching and course of the ulnar nerve in the forearm and hand. *Clin Anat* 17, 64–66.
- Braus, H., Elze, C., 1929. *Anatomie des Menschen. Ein Lehrbuch für Studierende und Ärzte. Vol. I*, 2nd Edition. Springer, Berlin.
- Bucher, O., 1943. Über die Varietäten des M. abductor digiti quinti. *Anat. Anz.* 94, 317–324.
- Gudemez, E., Tekdemir, I., Uslu, M., Eksioğlu, F., Elhan, A., 2002. Innervation pattern of the abductor digiti

- minimi muscle of the hand. *J Hand Surg (Br)* 27, 435–439.
- Harvie, P., Patel, N., Ostlere, S.J., 2004. Prevalence and epidemiological variation of anomalous muscles at Guyon's canal. *J Hand Surg (Br)* 29, 26–29.
- Kanaya, K., Wada, T., Isogai, S., Murakami, G., Ishii, S., 2002. Variation in insertion of the abductor digiti minimi: an anatomic study. *J Hand Surg (Am)* 27, 325–328.
- King, T.S., O'Rahilly, R., 1950. M. palmaris accessorius and duplication of M. palmaris longus. *Acta Anat.* 10, 327–331.
- Leonhardt, H., Tillman, B., 1988. Obere Extremität. In: Leonhardt, H., Tillman, B., Töndury, G., Zilles, K. (Eds.), *In Rauber/Kopsch Anatomie des Menschen Lehrbuch und Atlas Band IV*. Thieme, Stuttgart New York, pp. 370–432.
- Murata, K., Tamai, M., Gupta, A., 2004. Anatomic study of variations of hypothenar muscles and arborization patterns of the ulnar nerve in the hand. *J Hand Surg (Am)* 29, 500–509.
- Netscher, D.T., Cohen, V., 1998. Ulnar nerve entrapment at the wrist: cases from a hand surgery practice. *South Med J* 91, 451–456.
- Putz, R., Pabst, R., 1999. Sobotta, *Atlas der Anatomie des Menschen Band 1*, 21st Edition. Urban & Fischer, München.
- Tillman, B., Töndury, G., 1987. Obere Extremität. In: Leonhardt, H., Tillman, B., Töndury, G., Zilles, K. (Eds.), *Rauber/Kopsch Anatomie des Menschen: Lehrbuch und Atlas Band I*. Thieme, Stuttgart, New York, pp. 309–442.
- Wahba, M.Y., Singh, G.D., Lozanoff, S., 1998. An anomalous accessory flexor digiti minimi profundus muscle: a case study. *Clin Anat* 11, 55–59.
- Williams, P.L., Warwick, R., Dyson, M., Bannister, L.H., 1989. *Cervical Ventral Rami*. Gray's Anatomy, 37th Edition. Churchill Livingstone, New York, pp. 1127–1137.
- Wingerter, S., Gupta, S., Le, S., Shamasunder, S., Bernstein, R., Rabitaille, W., Kukuyeva, Y., Downie, S., 2003. Unusual origin of the flexor digiti minimi brevis muscle. *Clin Anat* 16, 531–533.